



RESENTING CLINICAL SIGNS

History: Presented for sore right front leg. Radiographs showed right-sided cardiomegaly. BNP 690.

DATE

10/26/22

ECHOCARDIOGRAPHIC FINDINGS

2D, M-mode, and Doppler study.

PERFORMED BY:

Dr. Brian Barnes

INTERPRETED BY

Keith Blass, DVM,
MS, DACVIM
(Cardiology)

Left atrial size is normal. The mitral valve appears normal, though trace mitral regurgitation is present. Left ventricular wall thickness is normal. Left ventricular internal dimensions are normal. Left ventricular systolic function is normal. The aorta and aortic valve are normal. Right atrial and right ventricular dimensions are normal. The tricuspid valve appears normal, though trace tricuspid regurgitation is present. TR velocity does not suggest the presence of pulmonary hypertension. The pulmonary artery and pulmonic valve appear normal, though trace pulmonic insufficiency is present. No shunting lesions are visualized. No pericardial effusion or cardiac masses are seen.

ECG during echo: Sinus arrhythmia

PATIENT

Toba Dixon

LA - 39.0 mm
IVSd - 13.1 mm
LVPWd - 10.1 mm
LVIDd - 45.3 mm
LVIDs - 32.5 mm
FS - 28%
RA - 26.0 mm
LVOT - 1.32 m/s
RVOT - 1.23 m/s
TR - 2.52 m/s

SPECIES

Canine

ASSESSMENT/RECOMMENDATIONS

BREED

Labrador Retriever

The only potential abnormalities seen in this exam are trace regurgitations of blood across Toba's mitral and tricuspid valves. It's likely that these represent normal physiologic variants, though the presence of very mild valvular dysplasia cannot be ruled out. The hemodynamic effects of the regurgitations are negligible at present, and the right-sided cardiomegaly noted in Toba's radiographs appears to be a normal variant.

SEX

MN

No therapy is recommended based on this exam.

AGE

1 y 9 mo

A recheck echocardiogram is recommended in 1 year to make sure that progressive regurgitation is not developing.

WEIGHT

35.9 kg

HOSPITAL NAME

Westview VH

REFERRING VET

Dr. Barnes



DATE

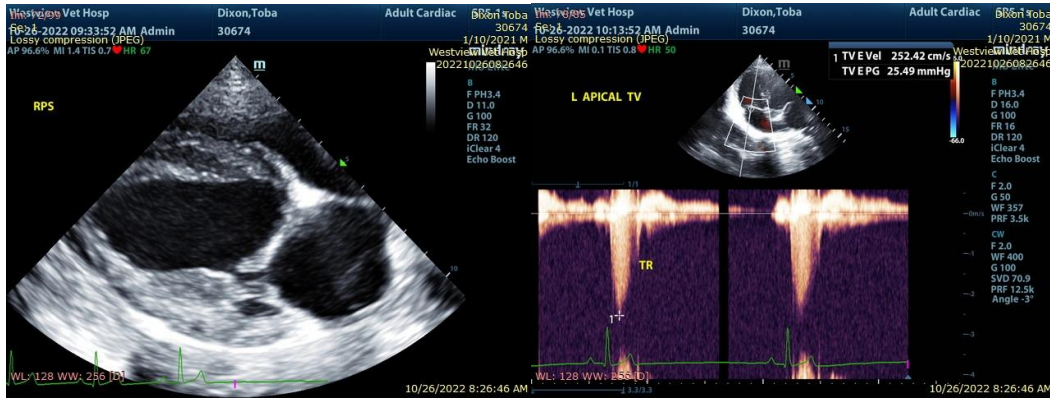
10/26/22

PERFORMED BY:

Dr. Brian Barnes

INTERPRETED BY

Keith Blass, DVM,
MS, DACVIM
(Cardiology)



The information and recommendations provided are based on the images presented by the referring veterinarian. No evaluation can be communicated regarding pathology that was not visible in the image/video clips provided.

PATIENT

Thank you for this referral. If the clinical or image interpretation does not parallel your findings or if I can be of any further assistance please contact me.

Toba Dixon

SPECIES

Keith Blass, DVM, MS, DACVIM (Cardiology)
KeithBlass@gmail.com
631-804-5754

Canine

BREED

Labrador Retriever

SEX

MN

AGE

1 y 9 mo

WEIGHT

35.9 kg

HOSPITAL NAME

Westview VH

REFERRING VET

Dr. Barnes